

Case report

The locked lumbar facet joint: intervention using mobilizations with movement

L. Exelby

Clinical Musculoskeletal Specialist, Pinehill Hospital, Hitchin, Herts, UK

INTRODUCTION AND BACKGROUND

The literature describes the presence of intra-articular structures in the zygapophyseal (facet) joint (Bogduk & Engel 1984, Bogduk 1997). The largest of these structures is attached via synovium to the inner surface of the superior and inferior capsules. They project up to 5 mm into the joint space. The apex of these structures is wedge-shaped and consists of densely packed collagen. Their functional significance is thought to be two-fold (Bogduk & Engel 1984, Bogduk 1997):

- I. to act as a passive space filler to provide greater stability;
- II. to protect the joint surfaces when they become unopposed during normal flexion and extension movements.

Giles and Taylor (1987) have reported that the capsule and synovial folds of the facet joint of the lumbar spine are richly innervated. In fact, the facet joints receive their nerve supply from the medial branch of the dorsal rami (Bogduk 1997).

Various authors (Mooney & Robertson 1976, Bogduk 1997) have shown that facet joint pain referral patterns occur predominantly in the buttock and thigh. However, symptoms can extend into the distal part of the lower limb (McCall et al. 1979). Mooney and Robertson (1976) demonstrated that injecting an irritant into the facet joints could diminish straight leg raise (SLR) and deep tendon reflexes.

Studies have used the response of pain relief to facet joint injection as indicative of facet joint pain (Schwarzer et al. 1994a, b, 1995). The incidence

of the facet joint causing low back pain is considered to be low compared to the disc (Kuslick et al. 1991, Schwarzer et al. 1994a, Bogduk 1997). In two studies, the proportion of cases with lumbar zygapophyseal joint pain varied from 15% in injured workers (Schwarzer et al. 1994a) to 40% in elderly patients (Schwarzer et al. 1995). Concurrent facet joint pain and discal pain were found to be rare (Schwarzer et al. 1994b). However, there is a great deal of controversy about the ability of clinicians to differentially diagnose facet and discal pathology, with most literature refuting the reliability of any clinical tests (Dreyer & Dreyfuss 1996, Revel et al. 1998).

An 'acute locked back' is characterized by the sudden onset of pain on attempting extension from a bent position. An upright stance cannot be achieved and there is resultant antalgic muscle spasm. The patient may present with a shift and traditionally the joint is manipulated (Bogduk & Jull 1985).

A spinal treatment developed by Mulligan (1999) involves the application of a sustained mobilization along the facet treatment plane while the patient actively performs the painful physiological movement. These techniques are called sustained natural apophyseal glides (SNAGs). They are applied in a cephalad direction either centrally to the spinous process or unilaterally to the transverse process or articular pillar of the vertebra.

The following case study will outline an effective method of reducing an 'acute locked back' when the facet joint is implicated.

PATIENT PRESENTATION

History

A 46-year-old female presented with right-sided lower back pain radiating toward the buttock after performing arm curls with a barbell in a position of lumbar spine flexion. She experienced sharp pain whilst returning from this flexed position. The incident occurred 3 days prior to attending phy-

Received: 1 October 2000

Accepted: 14 February 2001

Linda Exelby, BSc(Physio), GradDipManTher, MMACP, MMPAA, Clinical Musculoskeletal Specialist, Pinehill Hospital, Benslow Lane, Hitchin, North Herts SG4 9QZ, UK.

Correspondence to: LE. Tel: +44(0)1462 701 293; Fax: +44(0)1462 421968; E-mail: LExelby@compuserve.com

siotherapy. Functional movements of getting out of bed, putting on shoes, getting into a car and moving from sitting to standing were limited. She had a past history of episodic back and occasional leg pain. Past magnetic resonance imaging (MRI) showed disc degeneration at L4/5 and L5/S1. However, the symptoms she presented with did not match her 'usual' back pain.

Physical Examination

On examination, the lower lumbar spine and pelvis were flexed with extension in the upper lumbar spine. There was significant extensor muscle spasm and a slight shift of her shoulders away from the side of pain. All movements were limited to a quarter range by pain with left side flexion being the least painful. Straight leg raise (SLR) was full. Passive physiological intervertebral movements (PPIVMs) revealed a block into extension and right side flexion at L4/5 and to a lesser extent at L5/S1. Passive accessory intervertebral movements (PAIVMs) in flexion (lying over a pillow for comfort) revealed marked resistance and symptom reproduction during right unilateral postero-anterior palpation of L4 over the articular pillar. There was some minor stiffness at L5 on central and right unilateral postero-anterior testing. The sacrum was in neutral.

Treatment

The patient was positioned in four-point kneeling on the plinth. Rocking back toward her heels produced some discomfort on the right. There was a slight shift of the pelvis to the right. Crossing the right leg over the left corrected this shift. A strong central cephalad glide to the spinous process and then to the right articular pillar was performed on L4 as the patient rocked backward (Fig. 1). These glides were repeated a total of five times.

The patient was then returned to the prone position over the pillow. On re-assessment of the PAIVMs palpation findings, there was no resistance and only minor discomfort. With the patient in this prone lying position a cephalad glide on L5 was applied whilst active slow, small pelvic anterior tilt movements were performed (Fig. 2). Applying this glide to L5 resulted in a relative extension glide at the L4/5 facet joint. This was done to restore extension at the L4/5 joint. The glide applied by the physiotherapist must allow pain-free anterior tilt movement. The use of an anterior pelvic tilt instead of extension from the thoracic spine as proposed by McKenzie (1984) targets the lower lumbar spine extension more effectively. A strip of tape applied firmly across the erector spinae at the L4 level on the symptomatic side was added to reduce any residual spasm. Four-point

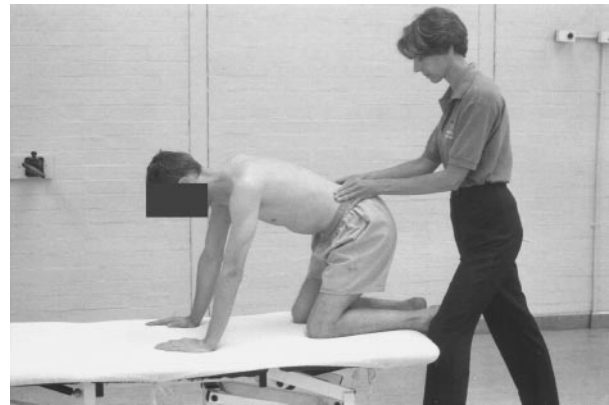

Fig. 1—A central SNAG applied to the L4 spinous process in 4-point kneeling with the model rocking back.

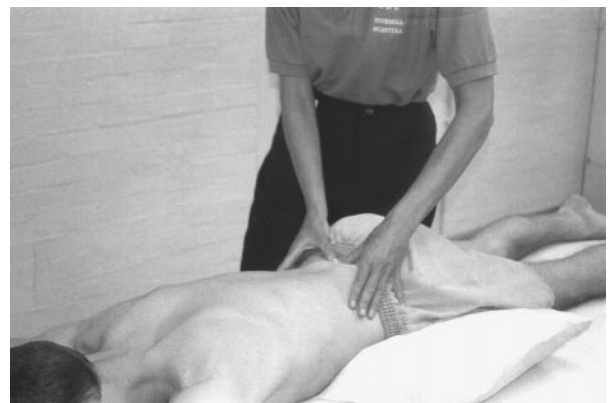

Fig. 2—Prone lying central SNAG applied to the L4 spinous process with anterior pelvic tilt and extension of the lower lumbar spine.

rocking and anterior tilting in prone were given as home exercises to maintain mobility.

DISCUSSION

During flexion of the functional spinal unit (FSU), the superior vertebra undergoes a combination of anterior rotation and anterior translation. The anterior rotation component of flexion is controlled by the posterior ligaments, muscles, facet capsule and the posterior annulus fibrosus of the disc, while the anterior translation is controlled by the anteromedial portion of the superior surface of the facet joint. Anterior rotation results in increased tension on the posterior annulus and increased compression on the anterior annulus. The anterior translation results in a small element of horizontal strain on the disc. This rocking forward of the superior vertebra over its disc results in an upward and slight backward glide of its inferior articular facet with a small gap between the inferior and superior articular surfaces occurring. The deeper segmental fibres of multifidus attach to

the posterior capsule of the facet joint. This attachment allows multifidus to protect the capsule from being caught inside the joint during movements (Bogduk 1997). Sustained flexion results in creep, with elongation of the above structures under a constant load (Twomey & Taylor 1982). Return to an upright stance results in a reversal of this rotation and translation.

Predisposing pathology

Age changes

Ageing causes biomechanical and structural changes of the lumbar spine, resulting in a change of mechanical properties (Bogduk 1997). Older lumbar spines show a greater amount of creep and hysteresis after prolonged deformation (Twomey & Taylor 1982). After the third decade, there is a gradual but definite decrease in mobility and increased stiffness in the disc as a result of biochemical changes. Facet joint age changes include vertical fibrillation of the anteromedial joint surfaces and splitting of the posterior cartilage longitudinally. A split piece of cartilage may remain attached to the capsule and form a false intra-articular inclusion. Where cartilage is lost, intra-articular inclusions may increase in size to fill the space vacated by the cartilage (Bogduk 1997).

Movement dysfunction

A clinical syndrome called lumbar segmental instability (LSI) has gained popularity in the physiotherapy world, with clinical features identified by O'Sullivan (2000). These features include recurrent episodes of acute 'locking'. LSI is thought to be the result of an increased neutral zone (Panjabi 1992). The neutral zone is defined as a region of intervertebral motion around the neutral posture where little resistance is offered by the passive spinal column. The neutral zone is shown to be increased with intersegmental injury and intervertebral disc degeneration (Panjabi et al. 1989, Panjabi 1992). Various segmental muscles have been shown to be responsible for controlling segmental joint play and proprioception in this neutral zone (Cholewicki et al. 1997). These muscles, which include the lumbar multifidus, are shown to be adversely affected in LSI (O'Sullivan 2000).

McFadden and Taylor (1990), with 'twist' computed tomography (CT) scanning, demonstrated that there was no gapping in the facet joints of a normal lumbar spine. Asymmetrical damage to the motion segment with traction spurs at joint margins, capsular tears and enlarged fat pads did, however, show gapping on 'twist' CT scanning. They hypothesized that gapping of a facet joint suggested a loss of segmental stability. This type of damage, together

with a lack of muscular segmental control, may contribute to the abnormal gliding of the facet joint surfaces with flexion and extension movements.

Theoretical proposals of acute locked back

1. *Entrapment theory* (Fig. 3A): The dense fibro-adipose apex of the facet joint (meniscoid) becomes trapped in a recess created by deformation of the articular cartilage. Any movement results in traction on the capsule through the base of the meniscus, resulting in pain and reflex muscle spasm (Bogduk & Engel 1984).
2. *Extrapment theory – facet* (Fig. 3B): Upon extension from a flexed position, the inferior articular process of the superior vertebra slides down towards its neutral position. The superior meniscoid, instead of re-entering the joint cavity, impacts against the opposite articular surface and is deflected into the adjacent subcapsular space. The meniscus buckles, forming a space-occupying lesion under the capsule. Pain occurs with any movement that causes further capsular distension, i.e. twisting and extension (Bogduk & Jull 1985).
3. *Entrapment theory – discal*: This other theory of extrapment proposes an intra-discal nuclear displacement down a partial radial fissure. Upon flexion, anterior compression displaces some nuclear

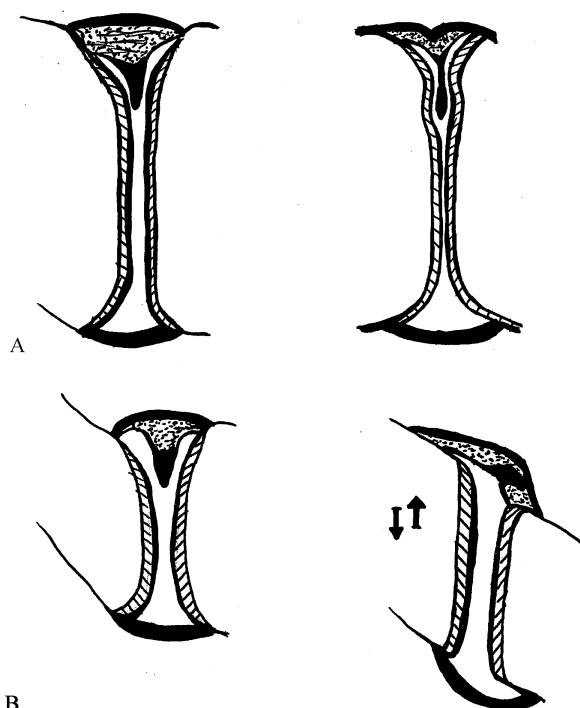


Fig. 3—(A) Meniscus entrapment theory, the meniscoid trapped in a recess. (B) Meniscus extrapment theory, the meniscoid deflected into the subcapsular pocket.

material posteriorly down the fissure where it becomes lodged amongst the well-innervated peripheral lamellae. Sudden extension compresses the posterior part of the disc with its nuclear 'satellite', evoking pain and discouraging further movement into extension (Bogduk & Jull 1985).

4. *The proprioceptive hypothesis:* The advocates of positional release (Chaitow 1998) propose a neurological concept whereby a sudden change of position, e.g. from trunk flexion to extension, can result in a sudden stretch of the annular spiral spindles of the shortened trunk flexor muscles, causing a reflex contraction and further shortening. The extensor trunk muscles that were on stretch in the flexed position are slow to respond to the sudden movement and are prevented from returning the trunk to neutral because of the tonically activated shortened flexor group. Further extension would result in a stretch on the trunk flexors and their resultant reflex contraction. This response may occur with or without joint pathology.

Proposed treatment approaches

Facet joint

Separation of joint surfaces with flexion and rotation as in a rotational manipulation manoeuvre is thought to reduce the intra-articular inclusion (Bogduk & Jull 1985).

Discal

Bogduk and Jull (1985) propose that a greater compressive force on the postero-lateral rim of the disc will encourage central migration of the satellite nuclear material. This could be achieved by placing the segment initially into flexion and performing a compressive side flexion manoeuvre. The segment is progressively positioned into extension whilst performing the side flexion technique.

Positional release

It is proposed that moving further into flexion, sustaining this position for a short while and then slowly returning the joints to their normal resting position allows time for the proprioceptor functions of the trunk muscles to reset themselves (Chaitow 1998).

Clinical reasoning and clinical findings

Initial treatments by the author using a SNAG into extension with the patient standing or sitting did not produce significant improvement in this clinical presentation, possibly for the reasons proposed by Bogduk and Engel (1984) and also by Chaitow (1998).

Performing a SNAG into flexion in standing or sitting positions was also found to be less successful, possibly because distraction and reduction of the meniscoid are prevented by the increased extensor muscle spasm that compresses the joint. A 4-point kneeling SNAG is described by Mulligan (1999), in which he states that it is useful for facet joint release following or prior to performing extension SNAGs in lying. He states that, if extension in lying is too painful, then only 4-point kneeling exercises should be performed.

The author has collected a further four case studies (see Table 1) with the above clinical presentation that have benefited from the revised treatment. The five cases were followed up by telephone over an average period of four months. All patients had previous episodes of back and leg pain with disc degeneration on radiological investigations. This supports the predisposing pathology theories outlined above.

Two patients (cases 1 and 4), whose symptoms were so severe that they could not be placed in a 4-point kneeling position, were treated in a side lying position of comfort. In both cases, the lumbar spine was in a flexed position. SNAGs were performed centrally or unilaterally with posterior pelvic tilt and lower lumbar spine flexion. The SNAG must ease any reproduction of symptoms that occur with this movement (Fig. 4). Release work can also be done in this position to the trunk flexor and extensors. Once posterior pelvic tilting is pain-free, a SNAG centrally on the spinous process into anterior pelvic tilt is performed to encourage intervertebral extension in this side-lying position.

The patient is gradually passively positioned into more lumbar spine extension (Chaitow 1998). Return to an upright position is done in various stages with the patient first sitting and performing posterior then anterior tilting. Applying a cephalad glide to the appropriate intervertebral level with these pelvic active movements will help clear any symptoms. To prevent further symptoms, ensure the patient moves from sitting to standing using a correct movement pattern. These patients required a further two treatments.

It has been the clinical experience of the author that patients will respond dramatically to intervention if a marked resistance is detected with unilateral postero-anterior palpation over the articular pillar at the symptomatic level. The clinical features described in this report, as well as the rapid response to the reported treatment, may implicate the facet joint. Where this resistance to palpation is less marked, the results are seldom as dramatic. Lack of rapid resolution could suggest a more complex pathology. Further treatment can be considered to deal with the movement pattern dysfunctions and to improve neutral zone stability.

Table 1. Presentation and treatment intervention of other acute locked back cases

Case	Sex	Age	Main subjective findings	Main objective findings	Treatment (Rx)	No of Rxs	Result at discharge
1	F	55	Gradual onset over 2 days after a lot of house-work. Severe right back pain.	Lower L SP flexed. Active & passive (L4/5) extension & RSF blocked. Right unilateral PA: L4 P>R.	4-point SNAG to L4 & L5=no improvement. Side-lying SNAG to L4 with posterior tilt then SNAG L5 with anterior tilt.	2	Minor pain. RSF & extension EOR discomfort.
2	F	29	Gradual onset. Increasing stiffness. Awoke unable to extend. Severe pain: central back & side of thighs.	Lower L SP flexed unable to straighten. Shift shoulders right. Right unilateral PA: L3 R>P.	4-point SNAG to L3 then SNAG to L4 in prone with anterior tilt.	1	Pain-free upright stance & extension 3/4 range minor discomfort.
3	M	49	Sitting flexion/rotation moderate right back pain when returned to upright position, 3 days before.	Active extension blocked & LSF limited. Right unilateral PA: L5 R>P.	4-point SNAG to L4 then SNAG to L5 in prone with anterior tilt.	1	Pain-free. Slight discomfort on EOR LSF.
4	F	65	Flexion to extension injury 4 days ago. Severe left-sided back/buttock pain.	Lower L SP flexed. Shift shoulder left. Active & passive (L3/4) extension & RSF blocked. Left unilateral PA: L3 & L4 P>R.	Side lying SNAG L3 & L4 with posterior tilt then SNAG L4 in side lying with anterior tilt. Progress to sitting SNAG.	3	Pain-free FROM.

Abbreviations: R, resistance; P, pain, RSF, right side flexion; LSF, left side flexion; PA, postero-anterior; EOR, end of range; FROM, full range of movement.

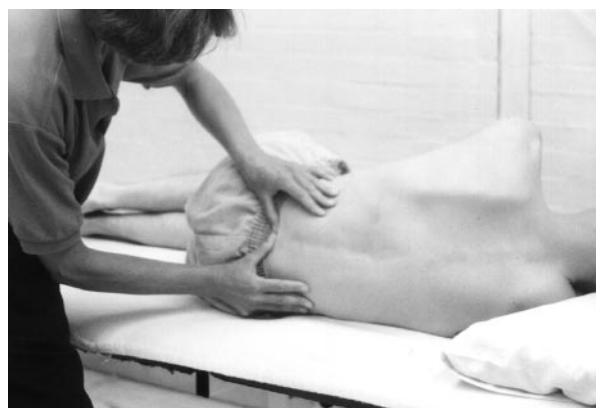

Fig. 4—Side lying SNAG applied centrally to the L4 spinous process whilst patient performs a posterior pelvic tilt.

CONCLUSION

The anatomy and mechanics of the lumbar facet joints, as well as their associated menisci, have been reviewed in relation to the production of symptoms. The proposed theoretical pathologies and clinical features of an acute locked back have been reviewed. The case presented in this report demonstrates an intervention to restore normal inter-segmental gliding using a mobilization with movement (MWM) in the 4-point rock back position which is followed by extension MWM of the lower lumbar spine. The treatment satisfies the theories proposed for the reduction of a facet joint lock.

Acknowledgement

The author would like to thank colleagues at Lister Hospital, Stevenage, UK for their assistance.

References

- Bogduk N 1997 Clinical anatomy of the lumbar spine and sacrum, 3rd edn. Churchill Livingstone, Edinburgh, p 15
- Bogduk N, Engel R 1984 The menisci of the lumbar zygapophyseal joints. A review of their anatomy and clinical significance. *Spine* 9(5): 454–460
- Bogduk N, Jull G 1985 The theoretical pathology of acute locked back: a basis for manipulative therapy. *Manual Medicine* 1: 78–82
- Chaitow L 1998 Positional release techniques. Churchill Livingstone, Edinburgh, p 10
- Cholewicki J, Panjabi MM, Khachatrian A 1997 Stabilising function of trunk flexor–extensor muscles around a neutral spine posture. *Spine* 22(19): 2207–2212
- Dreyer SJ, Dreyfuss PH 1996 Low back pain and the zygapophyseal (facet) joints. *Archives of Physical Medicine Rehabilitation* 77: 290–300
- Giles LFG, Taylor JR 1987 Human lumbar zygapophyseal joint capsule and synovial fold innervation. *British Journal of Rheumatology* 26: 93–98
- Kuslick SD, Ulstrom CL, Michael CJ 1991 The tissue origin of low back pain and sciatica. A report of pain response to tissue stimulation during operations on the lumbar spine using local anaesthesia. *Orthopedic Clinics of North America* 22(2): 181–187
- McCall IW, Park WM, O'Brien JP 1979 Induced pain referral from posterior elements in normal subjects. *Spine* 4(5): 441–446.
- McKenzie RA 1984 *The Lumbar Spine. Mechanical diagnosis and therapy.* Spinal Publications, Waikanae, New Zealand
- McFadden KD, Taylor JR 1990 Axial rotation in the lumbar spine and gapping of the zygapophyseal joints. *Spine* 15(4): 295–299
- Mooney V, Robertson J 1976 The facet syndrome. *Clinical Orthopaedics and Related Research* 115: 149–156
- Mulligan BR 1999 *Manual Therapy 'NAGs', 'SNAGs', 'MWMs' etc,* 4th edn. Plane View Services, Wellington, New Zealand

- O'Sullivan PB 2000 Lumbar segmental 'instability': clinical presentation and specific stabilizing exercise management. *Manual Therapy* 5(1): 2–12
- Panjabi M 1992 The stabilizing system of the spine 2. neutral zone and instability hypothesis. *Journal of Spinal Disorders* 5(4): 390–397
- Panjabi MM, Abumi K, Duranceau J, Oxland T 1989 Spinal stability and intersegmental muscle forces: a biomechanical model. *Spine* 14(2): 194–200
- Revel M, Poiraudreau S, Auleley GR et al. 1998 Capacity of the clinical picture to characterize low back pain relieved by facet joint anaesthesia: proposed criteria to identify patients with painful facet joints. *Spine* 23(18): 1972–1977
- Schwarzer AC, Aprill CN, Derby R, Fortin J, Kine G, Bogduk N 1994a Clinical features of patients with pain stemming from the lumbar zygapophyseal joints. Is the lumbar facet syndrome a clinical entity? *Spine* 19(10): 1132–1137
- Schwarzer AC, Aprill CN, Derby R, Fortin J, Kine G, Bogduk N 1994b The relative contributions of the disc and the zygapophyseal joint in chronic low back pain. *Spine* 19(7): 801–806
- Schwarzer AC, Wang S, Bogduk N, McNaught PJ, Laurent R 1995 Prevalence and clinical features of lumbar zygapophyseal joint pain: a study in an Australian population with chronic low back pain. *Annals of Rheumatic Diseases* 54: 100–106
- Twomey L, Taylor J 1982 Flexion creep deformation and hysteresis in the lumbar vertebral column. *Spine* 7(2): 116–122